

# Designing a new community lower limb haematoma pathway to prevent hospital admission and reduce cost

With advances in wound care and an increasing number of clinicians with the knowledge and skills in relation to tissue viability (TV) and wound management, we can diagnose and treat more complex wounds which would have previously required a hospital admission (Harrison, 2015). As a nurse-led team we found that haematomas were not being treated efficiently in the community, with patients often being sent to the acute setting for assessment and requiring surgery. As a TV team, it was deemed that we could manage these patients more effectively and appropriately in the community with early assessment and intervention of appropriate treatment. This may reduce the number of patients requiring surgical intervention and hospital admissions as well as associated costs. This led us to create a new community-based pathway for haematoma management. Previous treatment and management of haematomas in the local area was explored to ascertain effectiveness. This highlighted a gap in knowledge of the diagnosis of haematomas and delays in effective wound bed preparation. To address this as a team we explored primary dressing options and trialled a hydro-responsive wound dressing (HydroClean® advance) on 4 patients with a haematoma to their lower limb. We found that the dressing softened the haematoma, reduced pain, and prepared the wound bed for conservative sharp debridement (CSD). This article discusses in more detail the challenges of managing haematoma treatment and the development of a treatment pathway.

JO CONSTANT

*Lead Nurse for Tissue Viability and Wound Therapy, Tissue Viability Service, Medway Community Healthcare*

JO REED

*Tissue Viability Nurse Specialist, Medway Community Healthcare*

# Designing a new community lower limb haematoma pathway to prevent hospital admission and reduce cost

## KEY WORDS

- ▶ Wound care
- ▶ Haematoma
- ▶ Lower limb
- ▶ Hydro-responsive dressing

With advances in wound care and an increasing number of clinicians with the knowledge and skills in relation to tissue viability (TV) and wound management, we can diagnose and treat more complex wounds which would have previously required a hospital admission (Harrison, 2015). As a nurse-led team we found that haematomas were not being treated efficiently in the community, with patients often being sent to the acute setting for assessment and requiring surgery. As a TV team, it was deemed that we could manage these patients more effectively and appropriately in the community with early assessment and intervention of appropriate treatment. This may reduce the number of patients requiring surgical intervention and hospital admissions as well as associated costs. This led us to create a new community-based pathway for haematoma management. Previous treatment and management of haematomas in the local area was explored to ascertain effectiveness. This highlighted a gap in knowledge of the diagnosis of haematomas and delays in effective wound bed preparation. To address this as a team we explored primary dressing options and trialled a hydro-responsive wound dressing (HydroClean® advance) on 4 patients with a haematoma to their lower limb. We found that the dressing softened the haematoma, reduced pain, and prepared the wound bed for conservative sharp debridement (CSD). This article discusses in more detail the challenges of managing haematoma treatment and the development of a treatment pathway.

A haematoma to the lower limb is often classed as a trauma injury, where blood vessels have been damaged leading to bleeding into the tissues (Beldon, 2011). Haematomas are more prevalent in older people, with the majority occurring in those aged over 70 years (Laing et al, 2002). The collection of blood accumulates in the subcutaneous or intramuscular space, causing a build-up of pressure on surrounding capillaries which can lead to necrosis if not relieved (Thomson-Mchale, 2015). If the injuries are not managed appropriately the tissue damage can be extensive, requiring surgical intervention (Pagan and Hunter, 2011). Management involves prompt removal of the haematoma to reduce the risk of infection, minimise skin necrosis and damage, and to encourage healing (Karthikeyan et al, 2004); therefore, it is important that haematomas are identified and early intervention is commenced to ensure patients are on the correct pathway of care.

## Risk Factors

With advances in healthcare, people are living longer with a significant increase in the population aged 65 and older (McEvoy et al, 2022). In Medway in Kent, the population of over 65s was recorded as 45,273 by the local government in 2020 (Medway Council, 2021). With increased age comes an increase in pre-existing medical conditions (WHO, 2022), which as mentioned earlier increases the risk of developing a lower limb wound including haematomas.

With ageing, the skin becomes more fragile. With loss of moisture and elasticity, the epidermal layer becomes thinner with diminished cohesion between the dermal and epidermal layers, increasing the skin's vulnerability to trauma (Wounds UK, 2018).

Medication can increase a patient's risk of developing a haematoma, such as long-term steroid use which may cause thinning of the

## JO CONSTANT

*Lead Nurse for Tissue Viability and Wound Therapy, Tissue Viability Service, Medway Community Healthcare*

## JO REED

*Tissue Viability Nurse Specialist, Medway Community Healthcare*

epithelial tissue (Coondoo et al, 2014), increasing the vulnerability of the skin, which in turn, would lead to patients being at higher risk of developing more extensive damage rather than just a bruise. One study found that patients who were taking warfarin (an anticoagulant) had high incidence of developing pretibial haematoma (Thompson et al, 2014) and three of the case studies included in this article are an example of this.

Patients with limited mobility are at higher risk of knocking their limbs and accidentally causing damage, including skin tears and haematomas (Stephen-Haynes and Carville, 2011). Within the community nursing setting, a high percentage of lower limb wounds start with a trauma related injury. These wounds then become hard-to-heal due to the impact of multiple comorbidities requiring further assessment and treatment e.g. a doppler assessment (Wounds UK, 2020).

## DISCUSSION

Within Medway, we found that haematoma treatment pathways can be difficult to commence on initial presentation due to a lack of awareness and knowledge by both patients and healthcare professionals.

From reviewing local data in Medway, we found that patients would attend one of three professionals for help with their haematoma. We discovered that patients either attend A&E straight away, attend their local general practice (GP), or call for community nursing visits. Importantly, clinicians' knowledge and skills may have an impact on patients' treatment plans.

Patients that attended A&E often received surgical debridement and were admitted to hospital as an inpatient. A study found that the cost of an acute episode includes a mean of 11 bed days totalling £3,500 per patient, with some patients' hospital stays extending as long as 14 days (Thomson et al, 2014); however, this does not include the cost of community management post-discharge.

The demand on hospital beds has increased dramatically within the last 2 years as a result of the COVID-19 pandemic. Nationally, there are an estimated 3 million people aged 80 years or older with increasing hospital admission rates due to the presence of complex co-morbidities and frailty syndrome (NHS England, 2015).

Hospital admission is associated with risk of hospital acquired infection (HAI) and reduced mobility which can lead to hospital acquired pneumonia, deep vein thrombosis (DVT) and pressure ulcers. The National Health Service (NHS) long term plan highlights that care should be delivered as close to patients' homes as possible and that hospital admissions should be avoided (NHS Long Term Plan, 2019).

Within community organisations, where a patient developed a haematoma, we found that several patients would initially participate in self-care as they believed that their wound was a bruise. This would often cause a delay in appropriate treatment being initiated. When the haematoma failed to heal, patients often booked an appointment to see their GP. GPs in the local area lacked knowledge of haematoma physiology and would frequently refer these patients to the community nursing teams, stating that they had a 'wound to their legs', or to the hospital for acute assessment.

If the patient was referred to the community nursing team due to a lack of knowledge, the haematoma was often left untreated, believing that it would 'self-resolve' with no intervention or monitoring via community nursing visits. These haematomas did not self-resolve and were subsequently referred to tissue viability (TV) 2-3 weeks later when the wound was non-healing and sometimes infected.

These varied conservative treatment options that were given to patients caused significant delays in commencing an appropriate treatment plan to debride the necrotic haematoma tissue. This put patients at risk of wound infection and delayed healing (Beldon, 2011).

Once the patient was referred to TV, advice was given to the community nurses on wound bed preparation to soften and start autolytical debridement of the haematoma, as well as initiation of a full lower limb assessment. The patient was then booked an appointment with a tissue viability nurse (TVN) trained in conservative sharp debridement (CSD) when the devitalised tissue had softened and there were signs of demarcation from the wound edge (Leaper, 2002).

Overall, we found no consistency to the care being offered or delivered across the community

Previous treatment options	Outcome
Self-resolve	After 2 to 3 weeks of non-healing and often development of infection, the patient was referred to the tissue viability team
Referred to acute setting	Admitted for surgical debridement
Autolytic and conservative sharp debridement (CSD)	Honey dressing to start softening and debridement often took a long time to reach a stage suitable for tissue viability nurse to CSD
Larvae therapy	This is often difficult to obtain due to logistics in the community setting with local pharmacists, GP's prescriptions, and a reduction in nurse prescribers causing a significant delay in treatment

setting. Previous treatment options are highlighted in *Table 1*.

**CHALLENGES**


There was no recognition by all primary health clinicians that these patients had a lower limb wound and required a lower limb assessment, including an ankle brachial pressure index (ABPI). This would identify any arterial disease was present and if this is excluded, compression therapy could be started. This is the recommended treatment for lower limb wounds (NWCSP, 2020).

There was no formal pathway of care for this cohort of patients within the organisation.

Using soft intelligence by discussing with community nurses, we discovered that there was a lack of recognition of haematomas, how they develop and how they should be treated. Community nurses believed that if the haematoma wasn't open then this would self-resolve by applying a dry dressing.

This highlighted a knowledge gap within the community nursing teams. On reflection, the education provided by us as the TV team acknowledged that education around haematomas


Figure 1. Lower Limb Haematoma Treatment Pathway




### Lower Limb Haematoma treatment pathway

**Is it a Bruise or Haematoma?**  
**Haematoma:** palpable collection of clotted or partially clotted blood outside of the blood vessels under the surface of the skin, usually developed due to trauma  
**Bruise :** damage to small capillaries leading to bleeding into the subcutaneous layer of the skin showing colour changes on surface of skin, usually disappears after 2-3 weeks.


**Closed haematoma**



**Requiring autolytic debridement**



**Requiring autolytic & conservative sharps debridement**



**Aim**

- Protection and observe for haematoma to self resolve

**Treatment**

- Not suitable for debridement at this time
- Measure area
- Photograph with consent
- Advise patient to observe for signs of infection, deterioration and an open wound then inform clinician
- Clinician review in 1 week
- Holistic lower limb assessment to be completed within 2 weeks, including doppler ABPI
- Apply compression therapy dependant on results

**Aim**

- Debridement of soft devitalised tissue
- Reduce risks of wound infection

**Treatment**

- Measure/ Photograph area
- Dress with Honey or HydroClean® advance following TV advice
- Super absorber for exudate management
- Secure with profore 1 & 2 bandages toe to knee
- Holistic lower limb assessment to be completed within 2 weeks including doppler ABPI
- Apply compression therapy dependant on results

*\*Refer to tissue viability team*

**Aim**

- Soften dry necrotic tissue to allow debridement by TVN
- Reduce risks of wound infection

**Treatment**

- Measure/ Photograph area
- Dress with HydroClean® advance following TV advice
- Super absorber for exudate management
- Secure with profore 1 & 2 bandages toe to knee
- Holistic lower limb assessment to be completed within 2 weeks
- Apply compression therapy dependant on results

*\*Refer to tissue viability team*

**Red flags:**

- Acute infection- Take observations, refer to GP for antibiotics
- Signs of sepsis- 999
- Arterial signs and symptoms – refer to TVN / vascular
- Is the wound still actively bleeding? Apply pressure and elevate the limb any concern dial 999

<https://www.medicalnewstoday.com/articles/321943>  
 Todhunter J (2021) Management of lower limb haematoma, JCN Vol 35, No 1  
 National Wound Care Strategy(NWCS). Lower limb- Recommendations for clinical care.  
 NWCS 2020



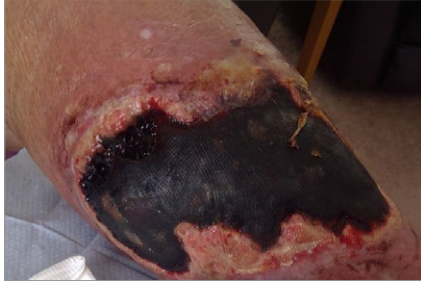

Figure 2A. Discharge from hospital (day 1) – HydroClean® advance treatment commenced on day 2

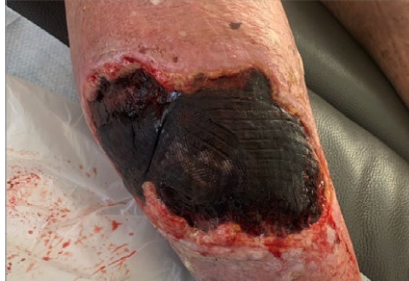

Figure 2B. Pre-conservative sharp debridement (day 5)

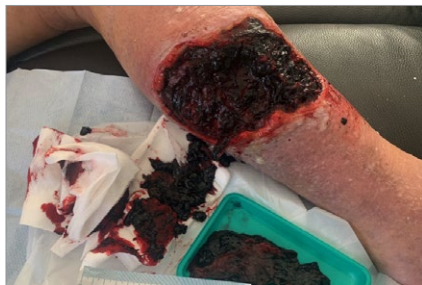

Figure 2C. Post-conservative sharp debridement (day 5)

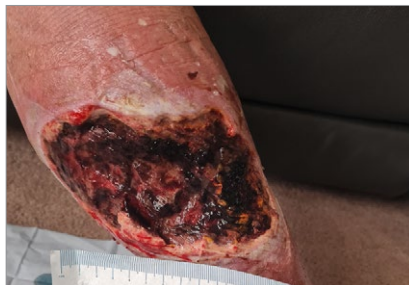

Figure 2D. Treatment with HydroClean® advance (day 6)

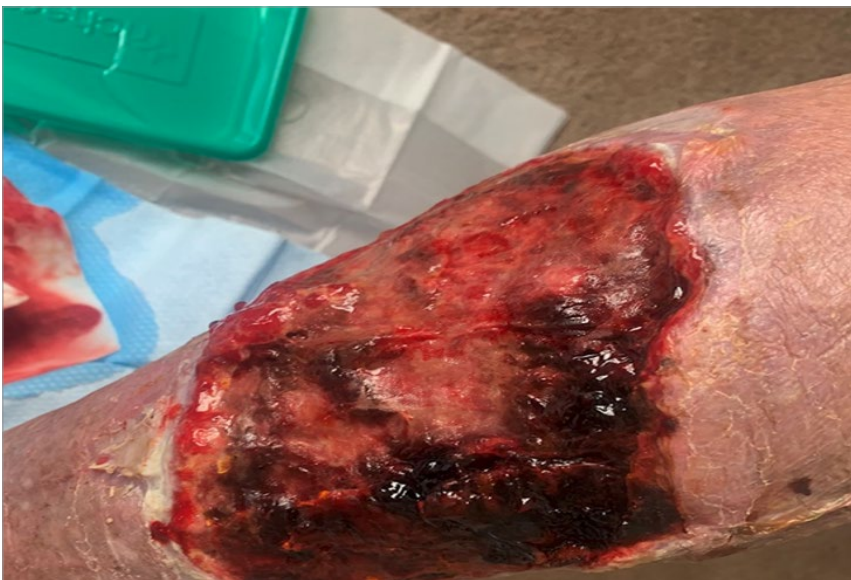

Figure 2E. 8 days of treatment with HydroClean® advance (day 14)

was not included within the lower limb courses that are delivered within the organisation.

#### METHOD

There were four patients who started on a new treatment pathway (Figure 1), which included

early recognition, fast referral to the TV team, application of recommended dressings and a lower limb assessment including ABPI.

HydroClean® advance is a primary dressing that donates ringers solution onto the devitalised tissue and facilitates autolysis by softening the tissue. We found that the dressing softened the haematomas and started to debride more rapidly than the honey-based products the community teams had been using previously. The TVNs and the local territory sales manager from the dressing company worked in partnership and provided clinicians with correct guidance on application techniques of the new dressing. The community nurses supplied regular wound photographs with patient consent to the TVN team, ensuring that as soon as the haematoma had softened and started to lift, the TVN could visit for CSD.

#### RESULTS

##### Case study 1

A 77-year-old man presented at A&E after a fall at home, knocking his right lower limb and sustaining a large haematoma (Figure 2A–E). He was discharged home following a short stay which included IV antibiotics and the haematoma being treated with honey dressings. Surgical debridement was considered and discounted.

Past medical history (PMH) included atrial fibrillation, sciatica, epistaxis and osteoarthritis. Medication included warfarin. He was the main carer for his wife. The patient was referred to the TV team by the community nurses after their first visit and the new treatment regime was started. The doppler assessment showed no signs of arterial disease and the gentleman was suitable for full compression therapy (40mmHg) via compression bandages. A visit was booked for TVNs to visit 10 days later as the haematoma had softened and lifted, allowing sharp debridement to be carried out in the home environment. Treatment continued with HydroClean® advance as there was still some haematoma to soften. After 7 days, further sharp debridement was achieved. The patient's treatment plan was then changed, as the necrotic tissue had all been removed, to a simple non-adherent dressing and compression therapy was continued. The patient subsequently healed after 10 weeks.

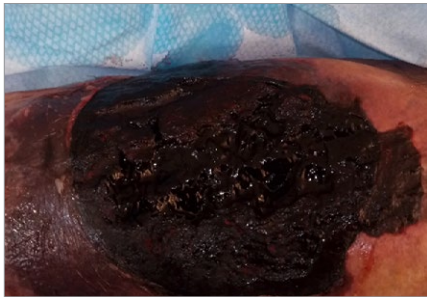


Figure 3A. Treatment changed to Hydroclean® advance after little progress observed with honey dressings (day 6)

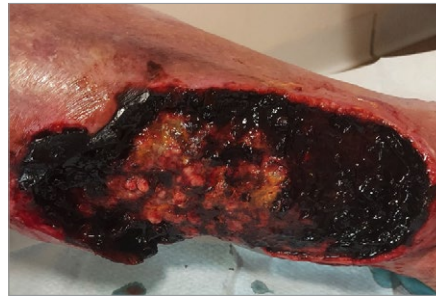

Figure 3B. Post-conservative sharp debridement (day 14)

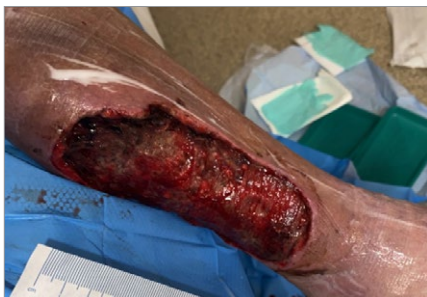

Figure 3C. 10 days of treatment with Hydroclean® advance (day 16)

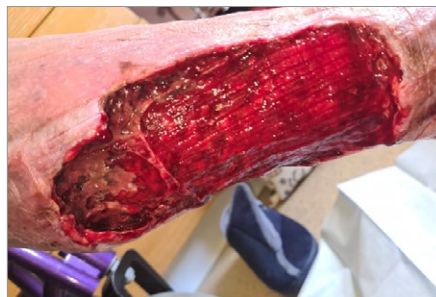

Figure 3D. Treatment with Hydroclean® advance (day 21)

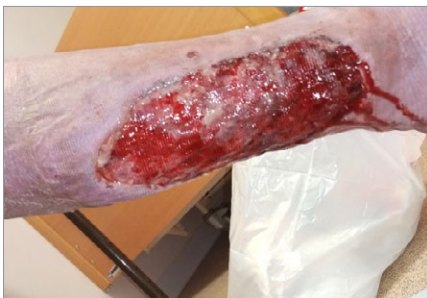

Figure 3E. Treatment with Hydroclean® advance (day 45)

### Case study 2

A 90-year-old lady presented to A&E following concern from carers in the residential home where she lives. She had knocked her leg and sustained a large haematoma to her left leg (Figure 3A–E). PMH included Alzheimer’s disease, hypertension, arthritis, bilateral knee replacements, and DVT to the left leg (2019). Medication included anticoagulant therapy. In A&E, she was assessed by the orthopaedic surgeons whereby they discounted surgical intervention. There was no evidence of infection at this stage and a decision was made for the anticoagulants to be discontinued, with the risk

of bleeding outweighing the risk of future stroke. 6 days post-discharge, the community nurses referred the patient to the TV team for advice. The community nurse had dressed the wound with a foam dressing initially and a TV visit was booked for the same day to review. On initial presentation, the wound to the patient’s left calf measured 14cm x 11cm. During this visit the top outer layer of the hardened haematoma was lifted using CSD and a honey dressing was applied. It was evident at initial assessment that this would require a collaborative effort to heal the wound involving community nurses working closely with TVNs to conduct multiple CSD treatments to remove the haematoma and progress wound healing. A holistic lower limb assessment was carried out and as the patient was deemed suitable for 20mmHg compression therapy, the treatment was commenced. 6 days after commencing the honey dressing, little progress was made; therefore, TV revisited and carried out further CSD and commenced HydroClean® advance to soften the haematoma further. Over the coming week, TV and the community nursing team worked closely. After 10 days (day 16) of using HydroClean® advance dressing, the wound had shown a marked improvement in the tissue present. At day 45, the wound had markedly reduced in size and depth. HydroClean® advance had been found to be effective in softening and lifting the haematoma as well as aiding a reduction in pain. Using the Numerical Rating Scale (where no pain=0, mild pain=1-3, moderate pain=4-6, and severe pain=7-10), 3 days after commencing HydroClean® advance, the patient’s pain score had reduced from 8 to 6 and the patient reported a score of 4, 7 days later.

### Case Study 3

An 81-year-old woman was referred to the community nurses from the GP after knocking her leg on the door of her car two days previously and sustaining a haematoma to the gaiter area of her leg. The patient had thought the area was just a bruise originally. As it grew in size, the patient called her GP for advice. The GP saw the patient, prescribed pain killers and asked the nurses to review to ensure the haematoma was healing well. The patient has a history of an underlying heart



condition and takes anticoagulation medication. The community nurses who originally visited did not recognise that this was a haematoma that wasn't going to resolve and would require further intervention and debridement. The patient was referred to the TV team one month later and advice was given to perform a lower limb assessment including ABPI, commence compression therapy and apply HydroClean® advance dressings. The lower limb assessment indicated that the patient had some venous disease, with the patient experiencing bilateral oedema and ankle flare. TV performed a home visit with the community nurses 9 days later. HydroClean® advance had aided the autolytic debridement of the necrotic tissue and allowed sharp debridement to take place. A large percentage of the hematoma was evacuated during this visit, but some remained, HydroClean® advance was continued for a further 4 weeks. At this time, the wound was granulating and the primary dressing was changed to a non-adhesive dressing. The patient's treatment was also changed to compression hosiery so she could self-manage, and she was referred to clinic as her mobility had improved. The patient reached full healing by week 21.

#### Case Study 4

An 80-year-old lady presented to A&E and was admitted following a fall at home. She was admitted after sustaining a large haematoma to her left leg. This was assessed by the orthopaedic surgeons and an evacuation and wash out of the wound was undertaken. PMH included hypertension, multiple falls, chronic kidney disease, and vertigo. The patient was referred to the community nursing team on discharge. The wound measured 14cm x 14cm and had a large amount of congealed blood present to the wound bed. This was referred to TV after the commencement of a medical honey dressing. On initial TVN review, the wound presented with 100% haematoma and necrotic tissue covering the surface of the wound with no symptoms of infection present. Consequently, CSD was carried out to remove the necrotic tissue. Following this, HydroClean® advance dressing was applied to aid further autolytic debridement. A full lower limb assessment was carried out with

ABPI as the patient was deemed suitable for 40mmHg compression therapy, this treatment was commenced. After 12 days, the wound was assessed as having 100% granulation tissue present and a month later, the wound had reduced in size to 9cm x 6cm.

#### CONCLUSION

From the four case studies, it was clear to see that through following a similar plan of care for patients with haematomas, healing outcomes improved by successful removal of the necrotic tissue and preparation of wound beds for healing. For all these cases, education on haematoma development and treatment were given to the community nurses managing these patients, which they stated they were not aware of previously. Three of the patients in the study that followed the same plan of care have subsequently healed at the time of writing this article and one has nearly healed. We also concluded that an added benefit of using the hydro-responsive dressing was a reduction in pain, with patients voicing it to be a cooling and soothing dressing. There was evidence of reduced costs as the majority of patients did not require hospital admissions or surgery. This also reduced the risk of HAI and time away from the home environment.

Using the outcomes from the case studies, a community-based pathway was developed in partnership with industry and is now in place. A teaching programme has been developed and added into the TV training package to increase awareness and knowledge on early diagnosis and the commencement of care plans. WUK

#### REFERENCES

- Beldon P (2011) Haematoma: assessment, treatment and management. *WoundEssentials*6:36-9
- Coondoo A, Phiske M, Verma S, Lahiri K (2014) Side-effects of topical steroids: A long overdue revisit. *Indian Dermatol Online* 5(4):416–25. <https://doi.org/10.4103%2F2229-5178.142483>
- Harrison M (2015) Day in the life - Lead tissue viability nurse. *Br J Nurs* 24(6): S44. <https://doi.org/10.12968/bjon.2015.24.Sup6.S44>
- Karthikeyan GS, Vadodaria S, Stanley PR (2004) Simple and safe treatment of pretibial haematoma in elderly patients. *Emerg Med J* 21(1):69–70. <https://doi.org/10.1136%2Femj.2003.005801>
- Laing R, Tan S, McDouall J et al (2002) Pretibial injury in patients in patients aged 50 years and over. *NZ Med J* 115(1167):274–85
- Leaper D (2002) Surgical debridement. *World Wide Wounds*. Available at <https://tinyurl.com/5yk3tbxc> (accessed 17 October 2022)
- McEvoy L, Richter M, Chen T et al (2022) Frailty among older surgical

- patients and risk of hospital acquired adverse events: The South-Western Sidney frailty and nurse sensitive indicators study. *J Clin Nurs* 1–8. <https://doi.org/10.1111/jocn.16259>
- Medway Council (2021) Population 2020. <https://tinyurl.com/b46f7tjh> (accessed 17 October 2022)
- National Wound Care Strategy Programme (2020) Lower Limb Recommendations for Clinical Care. <https://tinyurl.com/y9v8t4b9> (accessed 17 October 2022)
- NHS England (2015) Meeting the challenges of an ageing population. <https://www.england.nhs.uk/blog/catherine-thompson/> (accessed 17 October 2022)
- NHS England (2019) The NHS Long Term Plan 2019. <https://www.longtermplan.nhs.uk/> (accessed 17 October 2022)
- Pagan M, Hunter J (2011) Lower leg haematomas: Potential for complications in older people. *Wound Practice and Research* 19(1):21-28
- Stephen-Haynes J, Carville K (2011) Skintears made easy. *Wounds International* 2(4):1–6. <https://tinyurl.com/ywn5cm8c> (accessed 17 October 2022)
- Thompson-McHale S (2015) Haematomas: management and treatment. *Wound Essentials* 10(1):24–8. <https://tinyurl.com/4d8t94m7> (accessed 17 October 2022)
- Thomson W L, Pujol-Nicolas A, Tahir A, Siddiqui H (2014) A kick in the shins: The financial impact of uncontrolled warfarin use in pre-tibial haematomas. *Injury* 45(1):250–52. <https://doi.org/10.1016/j.injury.2012.07.007>
- World Health Organisation (2022) Ageing and health. <https://tinyurl.com/2f8wu4ts> (accessed 17 October 2022)
- Wounds UK (2018) Best Practice Statement: Maintaining skin integrity. *Wounds UK*. <https://tinyurl.com/36df3amr> (accessed 17 October 2022)
- Wounds UK (2020) Best Practice Statement: Management of lower limb skin tears in adults. *Wounds UK*. <https://tinyurl.com/yckf5r4f> (accessed 17 October 2022)