

# A new approach to debridement of wounds in people with diabetes: A case study series

Samantha Haycocks

**Citation:** Haycocks S (2017) A new approach to debridement of wounds in people with diabetes: A case study series. *The Diabetic Foot Journal* 20: XX–XX

## Article points

1. Real life case studies have shown that HydroClean® plus is an effective treatment for use in diabetic foot ulcers.
2. Debridement of devitalised tissue is a key element in treating diabetic foot ulcers. HydroClean plus has been shown to be very successful in this respect.
3. Diabetic foot ulcers require wound dressings that can manage exudate, such as HydroClean plus.

## Key words

- Devitalised tissue
- HydroClean® plus
- Wound healing.

## Author

Samantha Haycocks is advanced podiatrist, Salford Royal NHS Foundation Trust, Salford

**This article aims to evaluate the impact of a hydro-responsive wound dressing (HydroClean® plus) on debridement and wound bed preparation in people with diabetic foot ulcers. A selection of case studies from a case study series evaluation are presented. These demonstrate how HydroClean plus has been used as part of a wound management programme to remove devitalised tissue (slough and eschar), fully preparing the wound bed to enable healing to progress.**

Recent figures show that there are now 4.05 million people with diabetes in the UK (NHS, 2015). Diabetic foot ulceration leading to amputation is one of the main complications of diabetes (McInnes, 2012; Weledji and Fokam, 2014). It is estimated that at any one time there are approximately 68,000 people in England with a diabetic foot ulcer. Diabetes and its complications have an annual cost to the NHS estimated to be between £629 million and £786 million; 46% of patients with severe ulceration account for 80% of the costs (Kerr, 2017).

Managing a diabetic foot ulcer, healing it and preventing amputation if it deteriorates is a significant challenge (Frykberg and Banks, 2015). In order to support clinicians treating diabetic foot disease, guidelines have been developed on the best practice of managing diabetic foot wounds (International Best Practice Guidelines, 2013). A cornerstone of treatment is wound bed preparation and the use of debridement to remove devitalised tissue that hinders healing and forms a nidus for bacterial growth and infection (Kavitha et al, 2014). A number of debridement methods may be used which have varying levels of success and have different cost implications (Bennet et al, 2013; Yazdanpanah et al, 2015).

A new, unique debridement and cleansing treatment HydroClean® plus (HARTMANN) has been developed. HydroClean plus enables the removal of the devitalised tissue by the body's own

'safe' mechanism of autolysis and thus enables subsequent initiation of re-epithelialisation and healing (Atkin and Ousey, 2016).

This article presents a selection of case studies from a case study series evaluation that demonstrates how HydroClean plus has been used as part of a wound management programme to remove devitalised tissue (slough and eschar), fully preparing the wound bed to enable healing to progress.

## Methods

This work was carried out as a collective case study series. This involves studying multiple cases simultaneously or sequentially in an attempt to generate a broad appreciation of a particular issue (treatment regimen). This case study series was undertaken in an acute NHS Trust.

Patients with diabetes undergoing routine treatment for their wounds, but specifically in need of removal of devitalised tissue (eg slough/eschar) were entered into the evaluation.

HydroClean plus was used to remove devitalised tissue and prepare the wound bed for the second phase, re-epithelialisation and healing. Photographs of the wounds were taken to provide a visual record.

## HydroClean plus dressing

HydroClean plus consists of a superabsorbent wound dressing pad which creates a moist environment when applied in combination with Ringer's solution. The absorbent core of

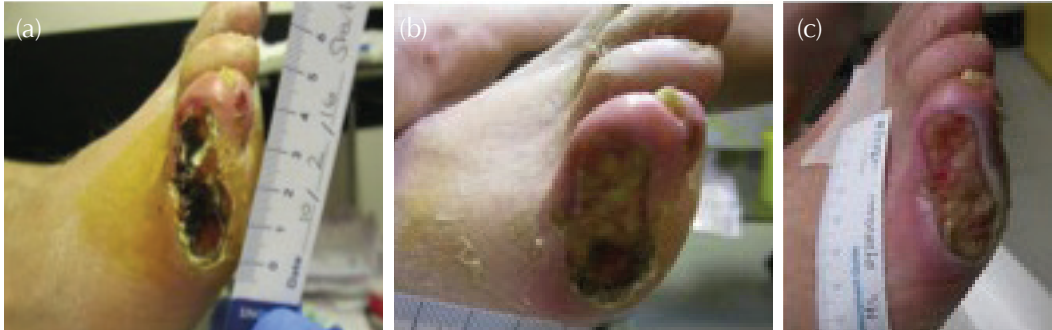


Figure 1. Case study 1 at (a) application of HydroClean plus. (b) On day 2, 80% of the necrotic tissue had been debrided. (c) Granulation tissue was present by day 5.

HydroClean plus is a superabsorbent polyacrylate (SAP) contained within a cellulose matrix. These polymers are able to absorb large amounts of fluid (Buchholz and Graham, 1998).

The material's ability to donate moisture and absorb bacteria and proteins within the pad is facilitated by the presence of Ringer's solution-activated SAP (Bruggisser, 2005; Eming et al, 2008). Bound bacteria and proteins are then removed from the wound when the dressing is changed. The antiseptic polyhexamethylene biguanide hydrochloride is bound to the SAP core.

The wound contact layer of HydroClean plus is composed of a non-adherent hydrophobic layer which conforms well to the wound surface. The presence of pores within the wound contact layer allows free exchange of Ringer's solution and wound exudate (Mwipatayi et al, 2005). This layer also contains silicone strips to prevent the dressing from adhering to the wound and aid atraumatic dressing.

## Ethics approval

This study was considered not to require formal ethical approval as during the evaluation the patients were not treated outside of their normal treatment regimen and the product was used according to its stated manufacturer's instructions for use. Local governance approvals for dressing evaluations were obtained.

## Results

### Case study patient 1

Mr X is 40 years old and was diagnosed with type 1 diabetes in 2006. He had palpable foot pulses and profound neuropathy, with extreme neuropathic pain. Mr X's diabetes control was suboptimal, with

his most recent HbA<sub>1c</sub> being 110mmol/mol. His ulceration was caused when he fell asleep with his foot on a radiator, and the burn wound subsequently became infected.

Oral flucloxacillin failed to treat the infection, so he was admitted for IV antibiotics. IV flucloxacillin did not improve the infection, so this was changed to IV tazocin. An X-ray at this time showed no evidence of osteomyelitis. After 5 days, Mr X was discharged, and commenced oral coamoxiclav. Unfortunately, the infection deteriorated again and he was readmitted for IV antibiotics.

The wound had become necrotic and was extremely painful. Mr X was unable to tolerate sharp debridement, so HydroClean plus was commenced, with the aim of actively debriding the wound with minimal pain for the patient (*Figure 1a*). The dressing was secured with wool and bandage and Mr X wore a derby sandal.

### Clinical outcomes

At day 2, 80% of the necrotic tissue had been debrided (*Figure 1b*) and on day 5 there was 70% granulation tissue present (*Figure 1c*). HydroClean plus had very quickly removed the devitalised tissue, promoting healing. Mr X also experienced reduced the pain levels with this dressing compared to previous dressings. However, his diabetes remained poorly controlled. A further X-ray revealed osteomyelitis was present in phalanges of the fifth toe, so Mr X decided to proceed with an amputation.

### Case study patient 2

Mr Y has type 2 diabetes (HbA<sub>1c</sub> 57) with renal failure and was on haemodialysis three times weekly. He had a previous history of colon cancer.

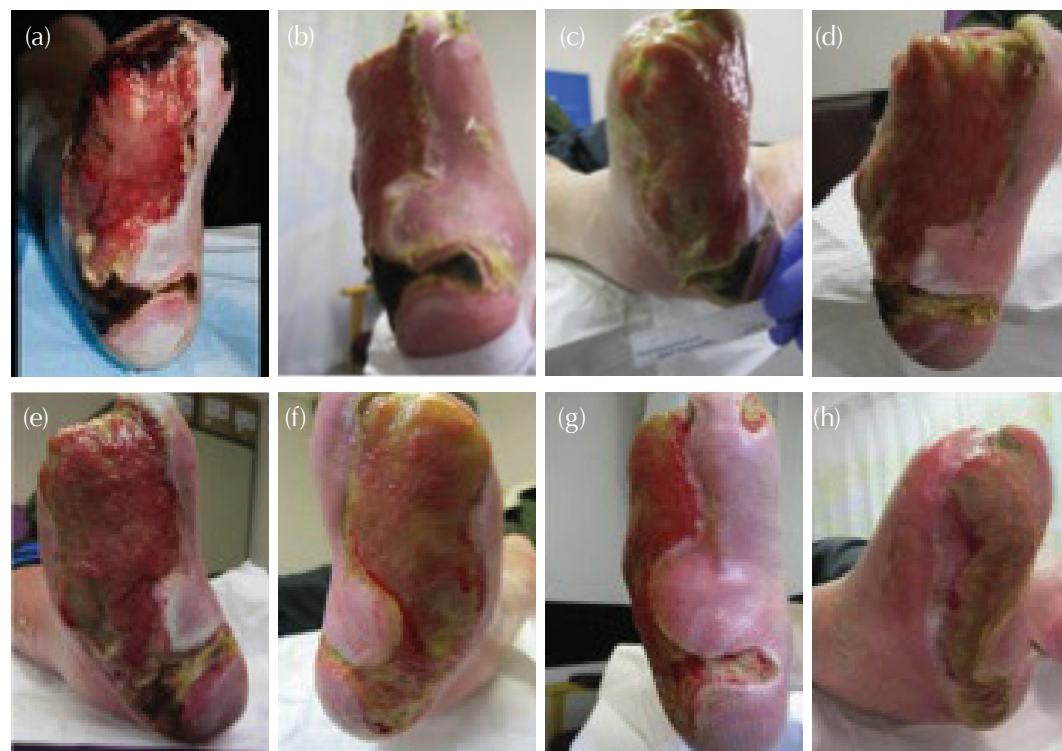

Figure 2. Case study 2 (a) Foot wound at presentation. (b) At day 7, some sharp debridement was possible. (c) At day 14, the area around the plantar heel was suitable for debridement. (d) At day 14, after surgical debridement. (e) Day 21. (f) Day 56. (g) Day 70 (h) Day 98.

Mr Y was referred via Trafford Diabetes team due to severe, and rapid deterioration of his neuro-ischaemic wounds which were potentially limb threatening. He was seen by the vascular consultant in the author's MDT clinic and referred immediately for surgical debridement and vascular intervention.

On discharge, he was referred back to the MDT clinic. The wound presented with adherent hard necrotic tissue areas (*Figure 2a*). HydroClean plus was commenced with a view to soften the devitalised tissue and aid its removal and enable wound bed preparation. The dressings were secured with wool and bandage and he was provided with a darco boot, but was minimally weight bearing and using a wheelchair.

#### Clinical outcomes

After 7 days, the necrosis was softening and the wound was able to be sharp debrided in places (*Figure 2b*). HydroClean plus was continued and the area around the plantar heel was debrided effectively at day 14 (*Figures 2c and d*).

An X-ray showed that there was deterioration of the osteomyelitis in the cuboid so Mr Y was switched from oral antibiotics to IV by the home IV team at 21 days (*Figure 2e*). The ongoing use of HydroClean plus enabled the wound to improve by removing the devitalised tissue and effectively promoting healing. (*Figures 2f-h*). IV antibiotics were stopped early January 2017 and at the time of writing the wound continues to improve.

#### Case study patient 3

Mr Z is a 62-year-old with type 2 diabetes, retinopathy, neuropathy, obesity and previous history of a pulmonary embolism. He had an amputation of the hallux and second toes due to severe infection resulting in gangrene and osteomyelitis.

Following surgery, the amputation site had 50% slough and 50% granulation. The head of the first metatarsal head was visible. Mr Z was receiving antibiotics and the wound had been treated with Acticoat flex and KerraMax care, but was failing

to progress. HydroClean plus was started with the primary aim to remove the devitalised tissue that was delaying the healing process. Dressings were secured with a layer of wool and kbandage, he was also provided with a dura sandal.

### Clinical outcomes

After one week the ulcer site had decreased in depth and the bone was no longer visible being covered by healthy granulation tissue. At week two the amputation site had decrease in size and depth. The wound improved during the 4 weeks of evaluation and decreased in size. The HydroClean plus dressing performed well to de-slough the wound. Over the treatment period, the wound slough reduced to 20% with 80% granulation. HydroClean plus was easy to apply and remove, and tolerance of the dressing was excellent.

### Discussion

In diabetic foot wounds, devitalised tissue (slough/eschar and debris) can:

- Prevent or delay a wound's normal healing process (Dabiri et al, 2014).
- Mimic or hide infection, attract bacteria to the wound, increasing the risk of infection (Kavitha et al, 2014).
- Prevent practitioners from assessing the extent and size of the wound, which is particularly problematic when staging pressure ulcer damage (Brown, 2013).
- Increase odour and exudate (Ousey and Roberts, 2016).

Devitalised tissue is known to provide an environment in which microorganisms can attach and form biofilms, resulting in wound infection (Percival and Suleman, 2015). This may lead to a more serious deep tissue infection that can be life

or limb threatening (Leaper et al, 2015). Therefore, a basic tenet of treating wounds is that any or all devitalised tissue must be removed and the wound prepared for healing, according to the TIME (Tissue, Infection, Moisture, Edge) management process (Pilcher, 2016).

The results of this study show that over the course of the treatment HydroClean plus reached its primary clinical objective of effectively and rapidly removing devitalised tissue and enabling good wound bed preparation. This rapid debridement promoted a healing response, leading to a positive healing outcome for the patients. In addition, both patient and clinician satisfaction was high in terms of the physical handling attributes of HydroClean plus (eg, application, atraumatic removal and exudate management).

These results are supported by several other clinical studies that have demonstrated successful results with HydroClean plus in the debridement and cleansing of chronic wounds (Cooper et al, 1988; Mähr, 2003; Paustian, 2003; Skórkowska-Telichowska et al, 2016; Atkin and Ousey, 2016; Spruce et al, 2016).

A hydro-responsive wound dressing such as HydroClean plus promotes autolytic debridement of devitalised tissue and slough and encourages new granulation tissue formation (Ousey et al, 2016a; Ousey et al, 2016b; Atkin and Rippon, 2016).

### Challenges using HydroClean plus

Autolysis is generally seen as a slow, painless method of removing devitalised tissue (Atkin and Rippon, 2016). However, debridement with HydroClean plus occurred very rapidly and in most of these cases a distinct change in the appearance of devitalised tissue was observed within 24–48 hours. For example, hard necrotic tissue became soft and

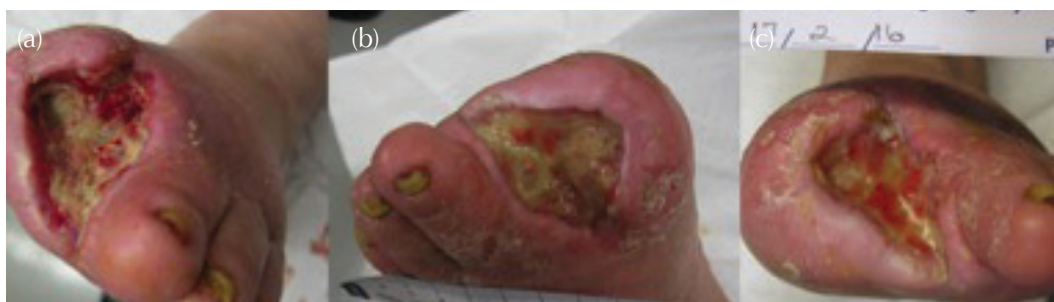

Figure 3. Case study 3 (a) Foot wound at presentation. (b) Day 14 (c) Day 28.

“mushy”, and was easy to remove with manual techniques such as surgical or sharp debridement. Slough liquefied to a great extent and was easily detached from the wound surface.

In some of these case studies, exudate was moderate to high and had to be managed to prevent tissue maceration. HydroClean plus manages exudate by exploiting the properties of superabsorbent polymers. It is a wet dressing that absorbs excess wound fluid but also provides moisture (Ringer’s solution) that aids in autolytic debridement (Rippon and Ousey, 2016). At first glance, the dressing appears too wet to be used because of a fear that it might cause maceration. However, in the course of this study little or no maceration was seen, although some incidents of hyper-hydration were apparent. Hyper-hydration does not have the same detrimental effects as maceration caused by exudate, and it is transient and non-damaging (Cutting et al, 2016; Rippon et al, 2016).

Due to the wetness of the dressing, fixation on these patients used a small amount of adhesive tape then a layer of wool bandage and Kband bandage to secure the dressing.

Pain is generally not a problem with diabetic foot ulceration, although in one case in this study the patient was in pain that was significantly reduced by using HydroClean plus. Pain reduction has been seen in other clinical studies with painful wounds such as venous leg ulcers and pressure ulcers (Atkin and Ousey, 2016; Spruce et al, 2016). A mechanism has been proposed by which this pain reduction might occur (Colegrave et al, 2016).

## Conclusion

This case study series has demonstrated the effectiveness of HydroClean plus primarily for cleansing and debridement of devitalised tissue in diabetic foot ulcers, but interestingly with the added bonus of promoting a healing response. The physical attributes of the dressing were rated highly not least in the management of wound exudate very well and positive feedback from the patients and clinicians was given. ■

- Atkin L, Ousey K (2016) Wound bed preparation: A novel approach using HydroTherapy. *Br J Community Nurs* **21**(Sup12): S23–8
- Atkin L, Rippon M (2016) Autolysis: mechanisms of action in the removal of devitalised tissue. *Br J Nurs* **25**(20 Suppl): S40–7
- Bennet H, Sewell B, Anderson P, et al (2013) Cost-effectiveness of interventions for chronic wound debridement: an evaluation in

- search of data. *Wounds UK* **9**(4 Suppl): 3–11
- Brown A (2013) The role of debridement in the healing process. *Nurs Times* **109**(40): 16–9
- Bruggisser R (2005) Bacterial and fungal absorption properties of a hydrogel dressing with a superabsorbent polymer core. *J Wound Care* **14**(9): 438–42
- Buchholz F, Graham A (1998) *Modern Superabsorbent Polymer Technology*. John Wiley & Sons, New York, USA
- Colegrave M, Rippon MG, Richardson C (2016) The effect of Ringer’s solution within a dressing to elicit pain relief. *J Wound Care* **25**(4): 184–90
- Cooper P (1998) TenderWet: an innovation in moist wound healing. *Br J Nurs* **7**(20): 1232–5
- Dabiri G, Damstetter E, Phillips T (2016) Choosing a wound dressing based on common wound characteristics. *Adv Wound Care* **5**(1): 32–41
- Eming S, Smola H, Hartmann B, et al (2008) The inhibition of matrix metalloproteinase activity in chronic wounds by a polyacrylate superabsorber. *Biomaterials* **29**(19):2932–40
- Frykberg RG, Banks J (2015) Challenges in the treatment of chronic wounds. *Adv Wound Care* **4**(9):560–82
- Hex N, Bartlett C, Wright D, et al (2012) Estimating the current and future costs of type 1 and type 2 diabetes in the UK, including direct health costs and indirect societal and productivity costs. *Diabet Med* **29**(7): 855–62
- International Best Practice Guidelines (2013) *Wound Management in Diabetic Foot Ulcers*. Wounds International, London. Available from: [www.woundsinternational.com](http://www.woundsinternational.com) (accessed 08.05.2017)
- Kavitha KV, Tiwari S, Purandare VB, et al (2014) Choice of wound care in diabetic foot ulcer: A practical approach. *World J Diabetes* **5**(4): 546–56
- Kerr M (2017) *Diabetic foot care in England: an economic study*. Insight Health Economics. Available from: <http://bit.ly/2pYUtwo> (accessed 08.05.2017)
- Leaper D, Assadian O, Edmiston CE (2015) Approach to chronic wound infections. *Br J Dermatol* **173**(2): 351–8
- Mähr R (2003) The mode of action of a superabsorbent polymer wound dressing. (TenderWet). *Ostomy Wound Manage* (Suppl):8–9.
- McInnes AD (2012) Diabetic foot disease in the United Kingdom: about time to put feet first. *J Foot Ankle Res* **5**(1): 26
- Mwipatayi BP, Angel D, Dixon P, et al (2005) Clinical experiences with activated polyacrylate dressings (TenderWet 24). *Primary Intention* **13**(2): 69–74
- Ousey K, Cutting KF, Rogers AA, Rippon MG (2016) The importance of hydration in wound healing: reinvigorating the clinical perspective. *J Wound Care* **25**(3): 122–30
- Ousey K, Roberts D (2016) Exploring nurses’ and patients’ feelings of disgust associated with malodorous wounds: a rapid review. *J Wound Care* **25**(8): 438–42
- Ousey K, Rogers AA, Rippon MG (2016a) HydroClean® plus: a new perspective to wound cleansing and debridement. *Wounds UK* **12**(1): 94–104
- Ousey K, Rogers AA, Rippon MG (2016b). Hydro-responsive wound dressings simplify T.I.M.E. wound management framework. *Br J Comm Nurs* **21**(Suppl 12): S39–49
- Paustian C (2003) Debridement rates with activated polyacrylate dressings (TenderWet). *Ostomy Wound Manage* (Suppl): 13–4
- Percival SL, Suleman L (2015) Slough and biofilm: removal of barriers to wound healing by desloughing. *J Wound Care* **24**(11): 498–10
- Pilcher M (2016) Wound cleansing: a key player in the implementation of the TIME paradigm. *J Wound Care* **25**(3 Suppl): S7–9
- NHS (2015) Quality and Outcomes Framework 2014–2015.
- Rippon MG, Ousey K, Rogers AA, Atkin L (2016) Wound hydration versus maceration: understanding the differences. *Wounds UK* **12**(3): 62–8
- Skórkowska-Telichowska K, Czemplik M, Kulma A, Szopa J (2013) The local treatment and available dressings designed for chronic wounds. *J Am Acad Dermatol* **68**(4): e117–26
- Spruce P, Bullough L, Johnson S, O’Brien D (2016). Introducing HydroClean® plus for wound-bed preparation: a case series. *Wounds International* **7**(1): 26–32
- Weledji EP, Fokam P (2014) Treatment of the diabetic foot – to amputate or not? *BMC Surg* **14**: 83
- Yazdanpanah L, Nasiri M, Adarvishi S (2015) Literature review on the management of diabetic foot ulcer. *World J Diabetes* **6**: 37–53